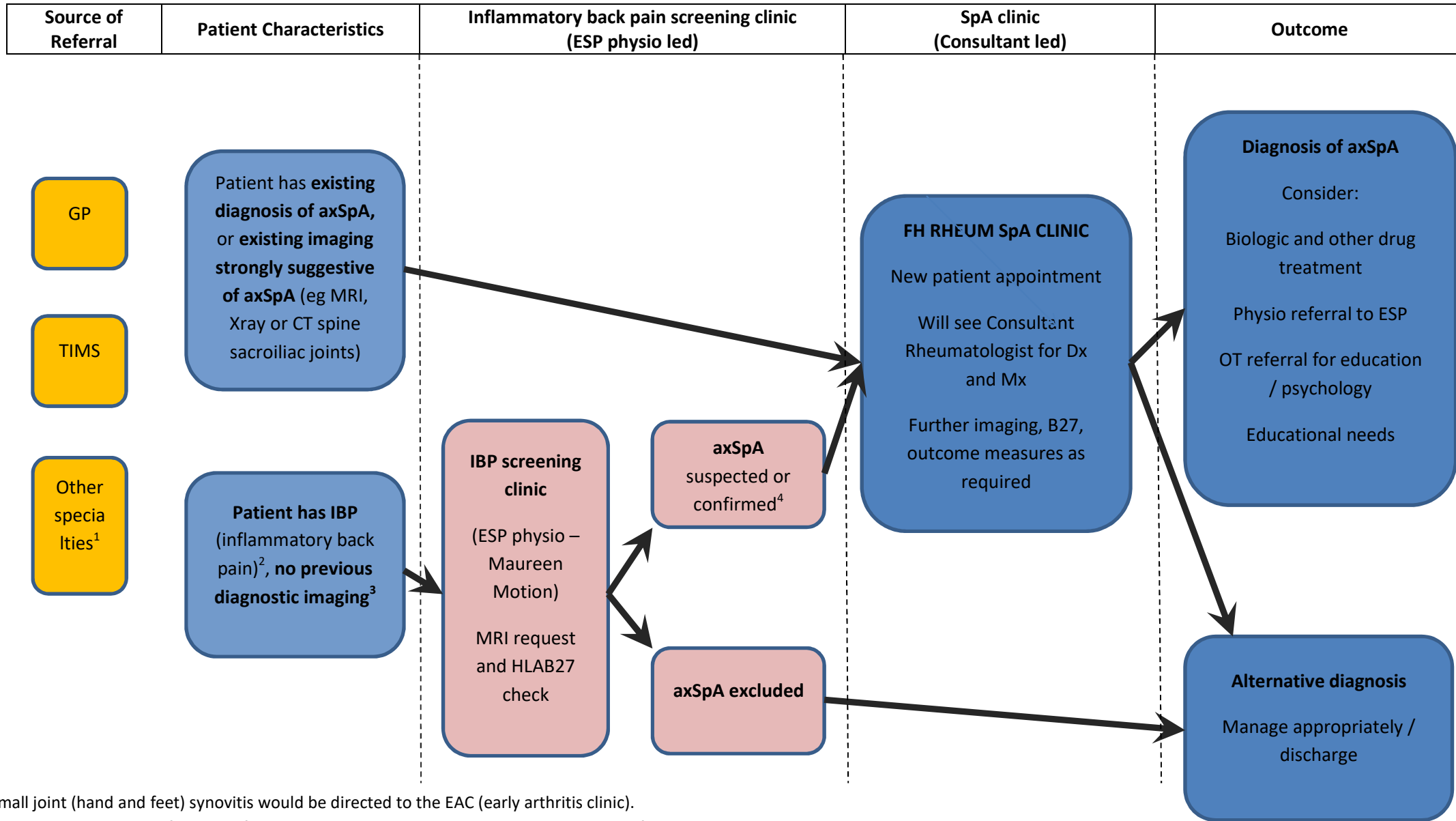


Newcastle Hospitals Suspected Axial Spondyloarthritis (axSpA) pathway - (Version 1, October 2020)



Small joint (hand and feet) synovitis would be directed to the EAC (early arthritis clinic).

Large joint disease with features of SpA would be seen in SpA F2F clinics, or F2F clinics of EP, RD, BT or LJK

¹ for example dermatology, eyes, gastroenterology

² IBP screening questions suggested: ASAS experts' criteria and ASAS list of SpA features from axSpA criteria

³ Other medical problems which would direct patient away from ESP physio clinic would be active malignancy, severe pain syndrome.

⁴ If imaging shows bilateral changes of bone oedema and / or erosions, and opinion of MSK radiologist is of axSpA, then diagnosis can be confirmed before seen in SpA clinic